Images of Memorable Cases: Case 142*

Herbert L. Fred, MD
Hendrik A. van Dijk

This work is produced by OpenStax-CNX and licensed under the
Creative Commons Attribution License 2.0†

External Image

Please see:
http://rup.rice.edu/memcases-button.jpg

Exercise 1 ***(Solution on p. 2.)***

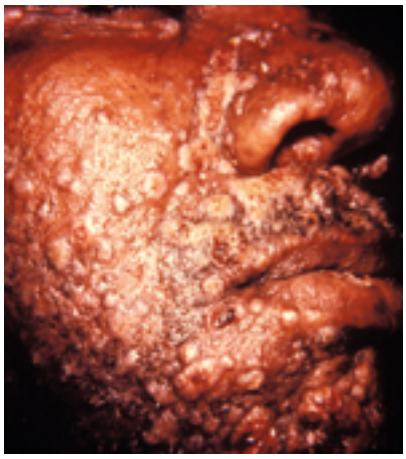

This 40-year-old homosexual man presented with weakness, weight loss, and painless, nonpruritic facial lesions of six weeks' duration. Similar skin changes were present over his legs and lower trunk. On physical examination, the lesions were papulopustular, round or oval, and sharply demarcated. They varied in size from a few millimeters to several centimeters. Many were umbilicated, some ulcerated, and a few crusted. The mucous membranes were normal.

*Version 1.3: Dec 3, 2008 10:35 pm -0600
†http://creativecommons.org/licenses/by/2.0/

Solutions to Exercises in this Module

Solution to Exercise (p. 1): 142. Malignant syphilis

Also known as syphilis maligna praecox and lues maligna, this is a rare but completely reversible variant of secondary syphilis. Although its incidence had been decreasing since the beginning of the 20th Century, the number of reported cases has increased of late, most of them in patients with HIV infection. The skin lesions are pleomorphic, appear in various stages of development, and become widespread, affecting the face and scalp most often. They begin as papulopustules, rapidly undergo necrosis, and tend to form deep crusts. Mucous membranes are involved in about a third of the cases. Histologic examination shows dense infiltrates of plasma cells and histiocytes along with obliterative vasculitis of medium-sized vessels. Spirochetes may be visible in the tissue sections, under dark field microscopy, or both. In addition, a reactive serologic test for syphilis, sometimes with very high titers, is the rule.

The differential diagnosis includes fungal infection, leishmaniasis, verrucous sarcoidosis, bartonellosis, leprosy, yaws, mycosis fungoides, and pyoderma gangrenosum.

The patient shown had positive serologic tests for syphilis, and after three weeks of penicillin therapy, his skin lesions resolved completely.